



**PATIENT**

Leo Carroll

**SPECIES**

Feline

**BREED**

DMH

**SEX**

Male Neutered

**AGE**

16.5 years

**WEIGHT**

17lbs

**INTERPRETED BY**

Maggie Machen  
 Lamy, DVM, DACVIM  
 (Cardiology)

**IMAGING PERFORMED BY**

Jenna Walsh, CVT

**HOSPITAL NAME**

VCA Westmoreland  
 Animal Hospital

**REFERRING VET**

Dr. Sullivan

**INVOICE**

24284

**DATE**

5/18/22

**PRESENTING CLINICAL SIGNS**

History: Annual exam. Chronic kidney disease IRIS stage 2. Grade 3/6 heart murmur. BP: 245, 235, 255mmHg. Assess prior to anesthesia.  
 -Radiographs: Cardiomegaly. No CHF.

**RADIOGRAPHIC FINDINGS** \*NOTE: Images submitted for supplemental cardiac information only.  
 Mild cardiomegaly. No obvious evidence of CHF.

**ELECTROCARDIOGRAPHIC FINDINGS** \*Note: Single lead ECGs are evaluated as a rhythm strip. Morphology/MEA cannot be definitively commented on.

A single lead ECG is available; 50mm/s, 20mm/mV. The average heart rate is 200bpm with a largely regular rhythm. The rhythm is sinus in origin, with a p for every QRS complex and vice versa. The P and QRS morphologies are positive. No ectopic beats, pauses or dysrhythmias observed.

ECG diagnosis: Normal sinus tachycardia.

**ECHOCARDIOGRAM FINDINGS**

2D, m-mode, color flow and doppler imaging is available. The left ventricular wall is normal in dimension. There is a diffusely hyperechoic endocardium consistent with fibrosis. The endocardium also appears remodeled. Borderline LV dilation. Remodeled, mildly hyperechoic papillary muscles. The left atrium is mildly dilated. The right atrium is normal in size. The right ventricle appears normal. No TR. The mitral valve is normal in structure and mobility. No MR. Blood flow through the LVOT is normal in velocity. Blood flow through the RVOT is normal in velocity. No PI or AI. No effusions or obvious cardiac tumors identified.

**CARDIAC CHART**

FELINE CARDIAC PARAMETERS	BODY WEIGHT (kg)	HR (BPM)	IVSd (cm) (Moise, Pipers)	LVIDd (cm) (Moise, Pipers)	LVWd (cm) (Moise, Pipers)	FS (%)	EF (%)
NORMAL PARAMETER	-----	150-240	0.35-0.55	<2 (mean 1.5)	3.5-0.55	35-67	80-100
PATIENT	7.7	190	0.52	1.8	0.52	63	93
FELINE CARDIAC PARAMETERS	LA/AO (Boon)	LA/AO HEART BASE (Swe) (Abbott)	LA 2D short axis Base view (cm) (Abbott)		LVOT VEL (m/s)	RVOT VEL (m/s)	E max (m/s)
NORMAL	<1.5	<1.3	<1.2		<1.6	<1.3	<0.9
PATIENT	1.7	1.5	1.5		1.2	1.1	NM

*\*Note: All measurements based upon multi-modal images and methods. An average value is reported.  
 Adapted from June Boon, Veterinary Echocardiography, 1998  
 Abbott J & MacLean H JVIM 2006;20: 111-119, Moise et al. Am J Vet Res 47:1476, 1986. Pipers et al. Am J Vet Res 40:882, 1979.*



**PATIENT**

Leo Carroll

**SPECIES**

Feline

**BREED**

DMH

**SEX**

Male Neutered

**AGE**

16.5 years

**WEIGHT**

17lbs

**INTERPRETED BY**

Maggie Machen  
Lamy, DVM, DACVIM  
(Cardiology)

**IMAGING PERFORMED BY**

Jenna Walsh, CVT

**HOSPITAL NAME**

VCA Westmoreland  
Animal Hospital

**REFERRING VET**

Dr. Sullivan

**INVOICE**

24284

**DATE**

5/18/22

**INTERPRETATION OF THE FINDINGS & FURTHER RECOMMENDATIONS**

Mild abnormalities are identified including mild LA dilation and borderline LV dilation. No evidence of significant hypertrophy ruling out typical hypertrophic disease. No other significant findings are identified. These abnormalities may suggest early Unclassified Disease; however, monitoring for progression is advised. No cause of the murmur is identified making it likely physiologic in origin. The ECG is unremarkable with a normal sinus tachycardia.

Given these findings, no medications are indicated as risk for complication at this time is low. Prognosis is guarded long-term until progression is assessed.

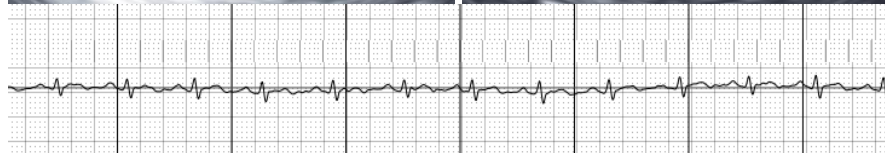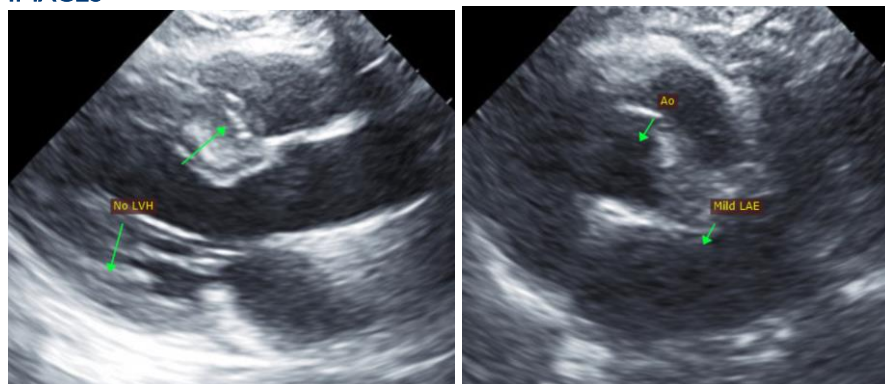
The reported blood pressure is markedly elevated, and should be reassessed for accuracy particularly given no reported clinical signs of severe hypertension (retinal changes, etc) or evidence of LVH on echo. Ideally obtain serial measurements in a controlled, low stress environment and continue until 3 consecutive readings plateau within 5mmHg of variability. If persistently >180mmHg despite a relatively calm demeanor, recommend institution of amlodipine to effect. Additionally if deemed accurate, screening for predisposing underlying causes of SHT is recommended (Cushings, PLN, adrenal tumor, etc), as primary disease is relatively uncommon and a rule out diagnosis.

Anesthetic risk is considered mildly elevated if needed, however judicious IV fluid rates are advised to avoid fluid overload. Additionally, drugs that stimulate heart rate should be avoided unless clinically necessary (glycopyrrolate, atropine).

Monitor for any development of clinical signs at home, including labored breathing, cough or signs of a blood clot (paralysis, neurologic change).

A recheck echocardiogram is recommended in 6 months to screen for progressive LA dilation, sooner if any issues arise in the interim.

**IMAGES**



The information and recommendations provided are based on the images presented by the referring veterinarian. No evaluation can be communicated regarding pathology that was not visible in the



**PATIENT**

Leo Carroll

**SPECIES**

Feline

**BREED**

DMH

**SEX**

Male Neutered

**AGE**

16.5 years

**WEIGHT**

17lbs

**INTERPRETED BY**

Maggie Machen  
Lamy, DVM, DACVIM  
(Cardiology)

**IMAGING  
PERFORMED BY**

Jenna Walsh, CVT

**HOSPITAL NAME**

VCA Westmoreland  
Animal Hospital

**REFERRING VET**

Dr. Sullivan

**INVOICE**

24284

**DATE**

5/18/22

image/video clips provided.

Thank you for this referral. This report was generated using transcription software, and minor dictation errors may be present. If the clinical or image interpretation does not parallel your findings or if I can be of any further assistance, please contact me.

**Maggie Machen Lamy, DVM**  
**Diplomate of the American College of Veterinary Internal Medicine (Cardiology)**  
info@sonopath.com